

ORIGINAL RESEARCH ARTICLE

Laparoscopic versus Open stoma creation: A retrospective analysis

Kengo Hayashi, Masanori Kotake, Masahiro Hada, Koichiro Sawada, Masahiro Oshima, Yosuke Kato, Kaeko Oyama and Takuo Hara

Department of Surgery, Koseiren Takaoka Hospital, Toyama, Japan

Abstract:

Objectives: This study aimed to compare open stoma (OS) creation with laparoscopic stoma (LS) creation considering the operation time, blood loss, time of oral intake, and complications. We also compared multiport LS and single-incision laparoscopic stoma (SILS) creation. **Methods:** We reviewed the demographic data, diagnosis, indications, operation time, blood loss, time of oral intake, operative procedure, and complications of 50 patients who underwent stoma creation between April 2014 and April 2016. **Results:** The mean blood loss was significantly lower in the LS group (7.85 ± 18.4 ml) than in the OS group (38.1 ± 73.2 ml; $P=0.02$). There were no statistical differences between the groups in terms of the operation time (LS, 72.1 ± 32.7 min; OS, 61.2 ± 31.2 min; $P=0.23$) or time of oral intake (LS, 1.0 ± 0 days; OS, 1.91 ± 2.71 days; $P=0.17$). Peristomal skin problems occurred in 11 patients (47.8%) in the OS group and 5 patients (18.5%) in the LS group. There were no statistically significant differences between the SILS and multiport LS groups, considering the operation time, amount of bleeding, and time of oral intake. **Conclusions:** LS is comparable with OS in terms of operation time and time of oral intake and may cause lesser blood loss. Considering its advantages, LS is a useful approach for patients requiring biopsies or intra-abdominal inspection. SILS is a minimally invasive technique, suitable for patients in whom the stoma site is preoperatively decided.

Keywords:

stoma, laparoscopic stoma creation, single-incision laparoscopic surgery

J Anus Rectum Colon 2017; 1(3): 84-88

Introduction

In recent years, laparoscopy has been effectively utilized for colorectal surgery worldwide. This approach decreases blood loss and postoperative pain, reduces the duration of hospitalization, and improves the quality of life¹⁾. As for stoma creation, several reports about laparoscopic surgeries have been described²⁻⁵⁾. The approaches used for stoma creation can be broadly classified into two groups: open stoma (OS) creation and laparoscopic stoma (LS) creation. Less invasive procedures, such as single-incision approaches, are also possible. Considering these less invasive procedures, single-incision laparoscopic stoma (SILS) creation or single-incision OS is superior to other procedures; however, SILS can extend the operative time because the technique is challenging. Laparoscopic surgery enables detailed intra-

abdominal inspection, accurate biopsy, and bowel selection that can be easily pulled to the desired stoma site. Each approach has benefits, but comparative analyses of these techniques are scarce. Therefore, we compared the clinical outcomes and advantages of LS and OS creations. Furthermore, we compared SILS with conventional multiport LS creations.

Methods

Patient selection

Data of 128 consecutive patients who underwent ileostomy or colostomy at a single institution (Department of Surgery, Kouseiren Takaoka Hospital) between April 2014 and April 2016 were retrieved from the database. Patients

Table 1. Procedures and Results.

	LS group (N=27)	OS group (N=23)	P*
Age (yr)			
Median	72	72	
Range	71±9.3	72±9.4	NS
Gender			
male/female	11/16	11/12	NS
Primary disease (%)			
Rectal cancer	12 (44)	3 (13)	0.028
Colon cancer	9 (33)	8 (35)	NS
Other cancers	4 (14)	8 (35)	NS
Malignant lymphoma	1 (3)	0 (0)	NS
Others	2 (6)	4 (17)	NS
Carcinomatous peritonitis (%)	3 (11)	5 (21)	NS
Indication for stoma (%)			
Complete obstruction	4 (14)	16 (70)	0.0001
Sub-obstruction	16 (59)	2 (8)	0.0002
Unable to resect/bypass	5 (18)	0 (0)	NS
Others	2 (6)	5 (21)	NS

NS: not significant

*Fisher's exact test

who required bowel resection were excluded, and the remaining 50 patients were included. Almost all patients were operated by surgeons specializing in colorectal surgery, but five emergency cases were treated by other surgical teams on duty. The method of stoma creation used was selected by the operating surgical team. In all patients except the emergency cases, the desired stoma sites were marked by an experienced enterostomal therapy nurse and a doctor. For single-incision operations, one stoma site was marked, whereas for the LS group, four possible stoma sites were marked and the best was chosen after intra-abdominal inspection. The clinical data analyzed in this study were operative time, amount of bleeding, complications, time of oral intake, and occurrence of peristomal skin problems. The operative time (minutes) was measured from the time of skin incision to the application of the last skin stitch. In patients who required implantation of a central venous port (CVP), the operative time excluded the duration of CVP implantation. The duration of hospitalization was not assessed because some patients remained in hospital after stoma creation for further treatment such as chemotherapy; hence, the hospitalization duration did not accurately reflect the degree of recovery. Data on peristomal skin conditions were recorded daily by primary nurses. We classified the occurrence of erosion around a stoma as a skin problem. This study was done in accordance with tenet of the Declaration of Helsinki (1975, as revised in 2008). The study protocol was approved by the ethics committee of the Kouseiren Takaoka Hospital.

Surgical techniques

Mostly, OS creation was performed through a single 3-4 cm incision at the preoperatively marked stoma site using

the "trephine stoma" single-incision open OS technique reported by Senapati and Phillips⁶. Eight patients in the OS group needed median laparotomy to inspect the abdominal cavity. The bowel intended for the stoma was pulled up, and the stoma was created at the planned site. Using the single-incision OS technique, it was difficult to select the bowel for the stoma because the stoma site had already been decided. In LS creation, three ports were routinely used. First, a 12-mm port was placed at the umbilicus, and then two 5-mm ports were installed in the upper- and lower-lateral quadrants. The 5-mm ports were placed on the opposite side of the planned stoma site, and one or two ports were added, if necessary. Usually, a 10-mm flexible laparoscope was selected (Olympus Corp., Tokyo, Japan). In this approach, four stoma sites were marked but not incised, and the bowel most suitable for placement at one of the planned sites was chosen. After selecting the stoma site, the site was incised and the bowel was extracted. In SILS creation, the first incision was similar to that of single-incision OS. After laparotomy, a Lap-Protector and EZ Access (Hakko Co., Ltd., Nagano, Japan) were placed into the incision site. Three 5-mm ports were installed through the EZ Access for a 5-mm flexible laparoscope (Olympus Corp.) and two pairs of operating forceps. In all procedures, the extracted bowel was sutured and fixed to the fascia and skin with 3-0 Vicryl sutures (Johnson and Johnson, New Brunswick, NJ, USA).

Statistical analysis

Continuous data are presented as means ± standard deviation and compared using the Mann-Whitney U test. Fisher's exact test was used in the analysis of contingency table. All statistical tests were two-tailed and $P < 0.05$ was considered as statistically significant.

Results

Of the 50 patients included in this study, 27 underwent LS creation and 23 underwent OS creation according to the operating surgeon's preference. Patient characteristics, diagnoses, and indications for stoma creation are shown in Table 1. The average age and sex ratio were similar between the groups. Sixteen patients (70%) had a complete obstruction in the OS group compared with four patients (14%) in the LS group.

The results are summarized shown in Table 2. No significant differences in operation time (LS, 72.1 ± 32.7 min; OS, 61.2 ± 31.2 min; $P = 0.23$) or time of oral intake (LS, 1 ± 0 days; OS, 1.91 ± 2.71 days; $P = 0.17$) were evident between the groups. The mean blood loss was significantly lower in the LS group (7.85 ± 18.4 ml) than in the OS group (38.1 ± 73.2 ml; $P = 0.02$). There were no conversions to laparotomy in the LS group. Considering the number of ports used during LS creation, 13 patients required 1 port, 12 required 3 ports, 2 required 2 ports, and 1 required 5 ports. CVP implantation was performed in seven patients in the LS group and one in the OS group. In five patients in the LS group,

Table 2. Summary of Results; LS Group vs. OS Group.

	LS group (N=27)	OS group (N=23)	P*
Surgical time (min)			
Median	65	54	
Range	72.1 ± 32.7	61.2 ± 31.2	NS
Blood loss (ml)			
Median	5.0	10	
Range	7.85 ± 18.4	38.1 ± 73.2	0.02
Time of oral intake (days)			
Median	1	1	
Range	1.0 ± 0	1.91 ± 2.71	NS
Number of ports	1port: 13, 2ports: 2, 3ports: 12, 5ports: 1	-	
Type of stoma			
Ileostomy	15	10	NS
Transverse colostomy	7	7	NS
Sigmoid colostomy	5	6	NS
Placing CVP	7	1	0.055
Transition to laparotomy	0	-	
Complications			
Skin problems	5	11	0.03
SSI	0	2	NS
Ileus	0	1	NS
Parastomal hernia	1	0	NS

NS: not significant, SSI: Surgical site infection

*Fisher's exact test

the region of the bowel planned for the stoma was changed from the sigmoid colon to the transverse colon or the ileum due to shortness of the bowel or sclerosis of the peritoneal metastasis. Two patients in the OS group who underwent median laparotomy developed incisional infections. Considering the major complications, parastomal hernia occurred in one patient in the LS group, and one patient in the OS group suffered postoperative ileus that was treated without surgery. Peristomal skin problems occurred in 11 patients (47.8%) in the OS groups and 5 patients (18.5%) in the LS group; there were significant differences between the two groups ($P=0.03$). Within LS creation, we also compared SILS and multiport LS; no statistical differences were observed between them in age, gender, primary disease, surgical time, blood loss, time of oral intake, and the incidence of skin problems. The result is shown in Table 3. The graph in Figure 1 compares the blood loss and surgical time between the OS and LS groups and surgical time between LS and SILS creation.

Discussion

Stoma creation is an essential technique for most surgeons. Conventional approaches for stoma creation require an open laparotomy incision; however, less invasive techniques, such as single-incision stoma creation, termed "trephine stoma" technique, have become popular⁶. In recent

Table 3. Summary of Results; Multiport LS Group vs. SILS Group.

	multi-ports LS group (N=14)	SILS group (N=13)	P*
Age (yr)			
Median	71	72	
Range	71±11	71±7.7	NS
Gender			
male/female	8/6	4/9	NS
Primary disease (%)			
Rectal cancer	4 (29)	8 (62)	NS
Colon cancer	5 (36)	4 (31)	NS
Other cancer	3 (21)	0 (0)	NS
Malignant lymphoma	1 (7)	0 (0)	NS
Others	1 (7)	1 (7)	NS
Surgical time (min)			
Median	76	70	
Range	88.1±47.1	69.5±27.9	NS
Blood loss (ml)			
Median	5.0	5.0	
Range	11.1±25.6	4.38±1.19	NS
Time of oral intake (days)			
Median	1	1	
Range	1.0±0	1.0±0	NS
Type of stoma			
Ileostomy	5	0	0.04
Transverse colostomy	5	2	NS
Sigmoid colostomy	4	11	0.006
Complications (%)			
Skin problems	5 (35)	3 (23)	NS
SSI	0 (0)	2 (15)	NS
Ileus	0 (0)	1 (7)	NS
Parastomal hernia	1 (7)	0 (0)	NS

NS: not significant, SSI: Surgical site infection

*Fisher's exact test

years, laparoscopic techniques have been adopted for various surgeries, including stoma creation. Since Khoo et al.⁷ first reported the technique of laparoscopic loop ileostomy, many less invasive techniques for stoma creation, including SILS and gasless LS creation, have been described⁸⁻¹⁴.

In this study, we analyzed data from patients who underwent stoma creation and discussed the indications for the surgical approaches used. Trephine stoma, SILS, and gasless LS creation, which are "scarless" methods of stoma creation, are considered minimally invasive; however, they require the selection of stoma sites before intra-abdominal inspection. For example, in patients with upper rectal cancer, which requires preoperative chemo-radiotherapy, the sigmoid colon is often the preferred stoma site. Nevertheless, the sigmoid colon is sometimes too short to be elevated sufficiently for stoma creation. In this situation, the transverse colon has to be used instead; however, this is difficult because the stoma site has already been incised and is usually not proximal to the site of the transverse colon. Consequently, the height of a sigmoid colon stoma can be inadequate despite mobiliza-

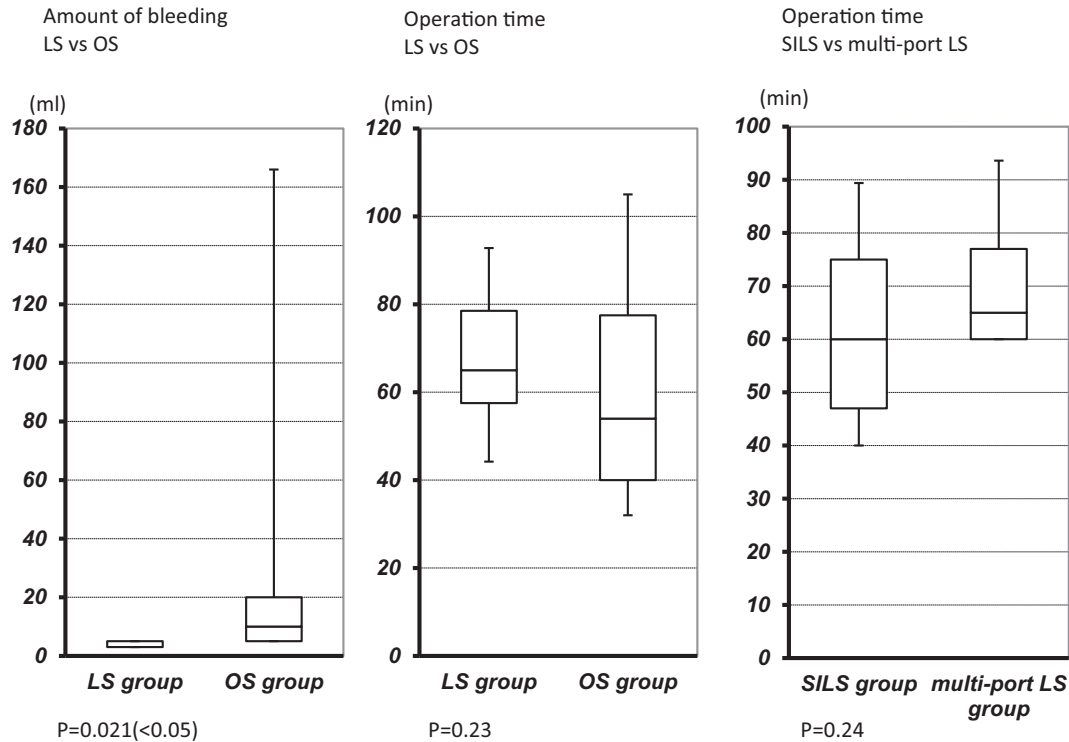


Figure 1. A graph demonstrating the differences in the blood loss and operation time between open and laparoscopic stoma creation.

tion, which can lead to complications. Michael and Michitaka¹⁵ noted that stomata less than 10 mm high are associated with a higher complication rate. Moreover, stomata that are intended to be temporary can become permanent depending on the state of primary cancer; hence, the height of stomata is very important.

LS creation not only minimizes surgical trauma but also allows for the inspection of the intra-abdominal cavity and guided biopsies, if necessary. In our study, the average operative time and the time of oral intake of the LS group were comparable to those of the OS group; however, the average blood loss in the LS group was significantly lower than that in the OS group. Thus, LS is a useful approach for patients who require biopsies or intra-abdominal inspection. There were no statistically significant differences in the blood loss, operative time, or time of oral intake between the LS and SILS groups; therefore, SILS is suitable for patients in whom the stoma site is decided preoperatively based on the findings of computed tomographic colonography or barium enema examination.

In five patients in the LS group, the region of the bowel planned for the stoma was changed due to shortness of the bowel or sclerosis of the peritoneal metastasis. This indicates that intra-abdominal inspection contributed to the selection of the bowel for the stoma. The incidence of peristomal skin problems was higher in the OS group (47.8%) than in the LS group (18.5%); this might suggest that the height of the stoma was inclined to be inadequate in the OS group, although we do not have the data of stoma height. Skin disorders can become a huge problem because they

make patients discontinue certain chemotherapeutic agents, such as bevacizumab, which repress the recovery of wounds. These results emphasize the importance of intra-abdominal inspection before incising the stoma site.

This study has several limitations. First, patients with complete bowel obstruction were excluded for LS creation because it is difficult to maintain a good visual field in the dilated bowel. This indicated that the proportion of emergency cases was higher in the OS group than in the LS group, and stoma building in the OS group became more difficult. This difference may have influenced the results. Second, this is a small, retrospective, single-center study, and the surgical approach was decided by the operating surgical team. Therefore, randomized controlled studies with additional cases from multiple centers are required to fully evaluate the safety and feasibility of this technique.

SILS is a less invasive procedure in terms of the number of scars¹⁰; however, it has disadvantages for patients in whom the stoma sites are undecided. In future, to combine reduced invasiveness and the advantages of laparoscopic surgery, SILS with the incision performed at the umbilicus should be considered. Using this technique, intra-abdominal inspection will be possible before stoma creation with minimal invasiveness. Furthermore, study of the advantages of this technique is warranted.

In this study, LS and OS were comparable in terms of the surgical time while the former presented with lesser blood loss. LS has several advantages; therefore, for cases wherein bowels are not dilated, especially those that need intra-abdominal inspection or biopsy, LS can be a good adaptation.

Moreover, for cases wherein the stoma site is decided preoperatively, SILS can be a suitable approach.

Conflicts of Interest

There are no conflicts of interest.

References

1. Clinical Outcomes of Surgical Therapy Study Group. A comparison of laparoscopically assisted and open colectomy for colon cancer. *N Engl J Med*. 2004 May;2004(350):2050-9.
2. Oliveira L, Reissman P, Noguera J, et al. Laparoscopic creation of stomas. *Surg Endosc*. 1997 Jan;11(1):19-23.
3. Schwandner O, Schiedeck THK, Bruch HP. Stoma creation for fecal diversion: is the laparoscopic technique appropriate? *Int J Colorect Dis*. 1998 Dec;13(5-6):251-5.
4. Lucia O. Laparoscopic stoma creation and closure. *Semin Laparosc Surg*. 2003;10:191-6.
5. Subhas G, Kim E, Gupta A, et al. Laparoscopic loop ileostomy with a single-port stab incision technique. *Tech Coloproctol*. 2011 Sep;15(3):337-9.
6. Senapati A, Phillips RK. The trephine colostomy: A permanent left iliac fossa end colostomy without recourse to laparotomy. *Ann R Coll Surg Engl*. 1991 Sep;73(5):305-6.
7. Khoo RE, Montrey J, Cohen MM. Laparoscopic loop ileostomy for temporary fecal diversion. *Dis Colon Rectum*. 1993 Oct;36(10):966-8.
8. Hellinger MD, Martinez SA, Parra-Davila E, et al. Gasless laparoscopic-assisted intestinal stoma creation through a single incision. *Dis Colon Rectum*. 1999 Sep;42(9):1228-31.
9. Liu J, Bruch H, Farke S et al. Stoma formation for fecal diversion: A plea for the laparoscopic approach. *Tech Coloproctol*. 2005 Apr;9(1):9-14.
10. Karen N, Zuri M, Phillip R. Scarless single-incision laparoscopic loop ileostomy: A novel technique. *Dis Colon Rectum*. 2011 Dec;54(12):1542-6.
11. Hoang M, Marlin W, Scott R et al. Single-port laparoscopic diverting sigmoid colostomy. *Dis Colon Rectum*. 2011 Dec;54(12):1585-8.
12. Subhas G, Kim E, Gupta A et al. Laparoscopic loop ileostomy with a single-port stab incision technique. *Tech Coloproctol*. 2011 Sep;15(3):337-9.
13. Junichi H, Masaki H, Ho M et al. Single-incision laparoscopic stoma creation: Experience with 31 consecutive cases. *Asian J Endosc Surg*. 2013 Aug;6(3):181-5.
14. Norikatsu M, Shiki F, Masayuki O et al. Standardized technique for single-incision laparoscopic assisted stoma creation. *World J Gastrointest Endosc*. 2016 Aug;8(15):541-5.
15. Michael K, Michitaka K. Avoidance and management of stomal complications. *Clin Colon Rectal Surg*. 2013 Jun;26(02):112-21.

Journal of the Anus, Rectum and Colon is an Open Access article distributed under the Creative Commons Attribution-NonCommercial-NoDerivatives 4.0 International License. To view the details of this license, please visit (<https://creativecommons.org/licenses/by-nc-nd/4.0/>).