

ORIGINAL RESEARCH ARTICLE

Rules for anal fistulas with scrotal extension

Yoshiro Araki¹⁾, Ryuzaburo Kagawa¹⁾, Hiroshi Yasui²⁾ and Masahiro Tomoi³⁾

1) Department of Proctology, Rakuwakai Otowa Hospital

2) Department of Pathology, Rakuwakai Otowa Hospital

3) PET-CT Examination Center, Rakuwakai Otowa Hospital

Abstract:

Objectives: To evaluate the rules for anal fistulas with scrotal extension, in particular, whether a high transsphincteric or suprasphincteric fistula, of which internal openings are usually located posteriorly, would extend into the scrotum. **Methods:** We retrospectively analyzed 446 consecutive male patients who underwent definitive anal fistula surgery. We compared fistulas with scrotal extension according to the location of the internal opening and divided them into anterior and posterior groups. **Results:** Forty-six (82.1%) of the 56 anal fistulas with scrotal extension had anterior internal openings. After excluding recurrent fistulas, 42 (87.5%) of the 48 anal fistulas with scrotal extension had anterior internal openings. The relative risk of scrotal extension in the anterior group was 14.22 times higher than that in the posterior group (95% CI: 7.43-27.21; $p < 0.0001$). After excluding recurrent fistulas, this relative risk rose to 18.67 (95% CI: 8.18-42.58), ($p < 0.0001$). **Conclusions:** Anal fistulas with scrotal extension are mostly low transsphincteric or intersphincteric with anterior internal openings. High transsphincteric or suprasphincteric fistulas rarely extend into the scrotum, except in recurrent cases.

Keywords:

anal fistula, scrotum, internal opening, seton

J Anus Rectum Colon 2017; 1(1): 22-28

Introduction

In some cases of men with anal fistulas, the fistula can extend into the scrotum, in which case the scrotum is usually painful and presents swelling, redness, and pus discharge from the external opening (secondary orifice) of the fistula. Although at first glance, such a presentation may be confused with acute scrotum diseases, examination by careful palpation reveals the anal fistulous tract between the external opening into the scrotum and the internal opening (primary orifice) into the anal canal.

Goodsall's rule for predicting the trajectory of anal fistulas is popular; however, the long-tract anterior fistula, which may also include fistulas with scrotal extension, is an exception of this rule^{1,2)}. To the best of our knowledge, the rules applicable to anal fistulas with scrotal extension and the suitable operative treatment are yet to be described in detail. Therefore, we investigated patients having anal fistulas with

scrotal extension who underwent definitive surgery at Rakuwakai Otowa Hospital.

Patients and Methods

Classification of anal fistulas

We defined the scrotal extension of the anal fistula as the presence of an external opening of the anal fistula on the wrinkled scrotal skin surface. If the external opening of the anal fistula was in the borderline area between the scrotum and perineal skin, we considered it as scrotal extension as well. In this study, we classified anal fistulas according to Parks' classification, which includes intersphincteric, transsphincteric, suprasphincteric, and extrasphincteric fistulas³⁾. Transsphincteric fistulas were further classified into low and high transsphincteric fistulas. We classified transsphincteric fistulas that slightly penetrated the superficial external

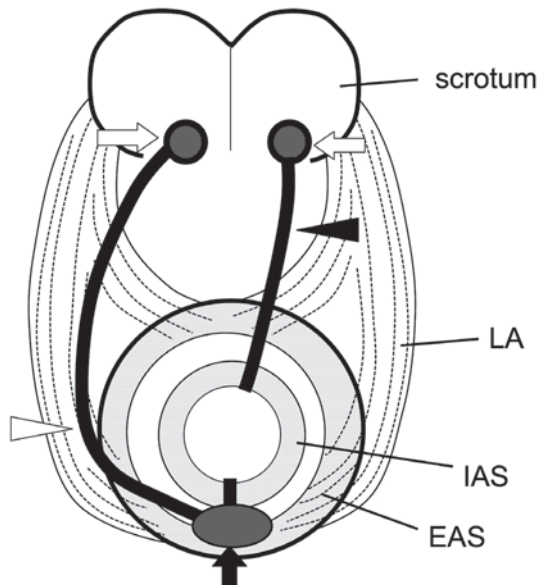


Fig. 1. Schema of two groups of anal fistulas with scrotal extension.

The fistula in the anterior group (black arrowhead) has an anterior internal opening and an external opening on the scrotum (white arrow). The fistula in the posterior group (white arrowhead) has a posterior internal opening, a primary abscess in the posterior deep space (black arrow), and an external opening on the scrotum (white arrow). IAS: internal anal sphincter, EAS: external anal sphincter, LA: levator ani

anal sphincter as low and those that penetrated the deep external anal sphincter as high. It was previously reported that high transsphincteric and suprasphincteric anal fistulas usually have a posterior internal opening and a primary abscess in the posterior deep space^{4,5}. In contrast, intersphincteric and low transsphincteric anal fistulas may have an internal opening and primary abscess in any direction, including anterior and lateral positions. The locations of the internal openings were expressed in clock positions; openings at the 10, 11, 12, 1, and 2 o'clock positions were classified as anterior, and those at the 3, 4, 5, 6, 7, 8, and 9 o'clock positions were classified as posterior (Fig. 1). If the internal position was located between o'clock positions, e.g., 1.5 o'clock, the location was expressed as a more lateral o'clock position, e.g., 2 o'clock.

Patients

A total of 446 consecutive Japanese male patients with anal fistulas who underwent definitive anal fistula surgery at our hospital between January 2010 and December 2015 were included in this study. Patients with Crohn's disease, ulcerative colitis or Fournier's gangrene were excluded. Patients treated at the outpatient unit who had subcutaneous anal fistulas were also excluded. Patients who underwent definitive anal fistula surgery before referral to our hospital were considered as having recurrent fistula. These included patients whose fistula was previously confirmed as healed and who subsequently developed the same fistula as well as

those for whom their original fistula did not completely heal before requiring a second surgery. Treatment with a simple drainage incision or drainage seton insertion was not considered as a previous anal fistula surgery. We retrospectively reviewed patient medical records, including operation records and magnetic resonance imaging (MRI) findings. The scrotal extension of the anal fistula was confirmed by the physical examination results reported in medical and surgical records. If anal fistulas were suspected to be complicated intersphincteric, transsphincteric, or suprasphincteric fistulas, MRI examination was performed preoperatively, according to our previously reported protocol⁵. We further analyzed a subgroup of 46 patients with intersphincteric and low transsphincteric fistulas that had anterior internal openings with scrotal extension. Each patient was followed up for at least 1 year after healing of their fistula was confirmed. Postoperative incontinence was assessed using patient interview, and the Wexner score was used to further assess patients who reported incontinence. Patients who scored greater than 10 points according to the Wexner score were classified as having major incontinence.

Surgical procedures

Two surgeons performed all operations, with patients in the prone jackknife position and under general anesthesia. If the fistulous tract in the scrotum was not excessively long (approximately less than 4 cm), minimal seton surgery was performed, as described by Tokunaga et al⁶. If the fistulous tract was long, then modified seton surgery was performed, during which the fistula was separated into two or more shorter sections⁷. For high transsphincteric and suprasphincteric anal fistulas, modified seton surgery was performed with MRI assistance⁵. In each surgery, disinfected rubber bands were used as both cutting and drainage setons. Most patients were discharged the day after the operation. The cutting seton band, inserted into the internal opening through the fistulous tract, was tightened every 2 weeks in the outpatient unit until the fistula was transected. The drainage seton bands were removed 2 or 4 weeks after the operation. The healing of the anal fistula was confirmed by the complete epithelialization of the wound after the fistula was transected by the cutting seton.

Statistical analysis

The relative risk (RR) and 95% confidence interval (CI) for scrotal extension were calculated. Statistical analysis was performed using a chi-squared test, and $p < 0.01$ was considered statistically significant.

Informed consent was obtained from all study participants. This retrospective study was approved by the institutional review board of our hospital.

Results

The clinical characteristics of the patients are summarized

Table 1.

a. Clinical Characteristics of Patients Having Anal Fistulas with Scrotal Extension. Data are presented as number of patients, except where indicated.

Characteristic	N=56
Sex	All male
Age (year), median (range)	38 (13-80)
Comorbidities	
Diabetes mellitus	2
Psychiatric disease	2
Hypertension	9
Obesity	2
Malignancy	2
Chronic renal failure	1
Disease duration (month), mean ± SD	54 ± 70
Side of scrotum with anal fistula	
Right	11
Left	41
Midline	1
Bilateral	3
Recurrent fistulas	
Yes	8
No	48
MRI examination	
Yes	44
No	12
Multiple fistulas	
Yes	21
No	35

MRI, magnetic resonance image; SD, standard deviation

b. Characteristics of Fistulas with Scrotal Extension Based on Parks' Classification and Location of the Internal Opening (o'clock). Two patients with multiple fistulas in which fistulas extended bilaterally were listed twice.

Parks' classification	Location of the internal opening (o'clock)												Total
	6	7	8	9	10	11	12	1	2	3	4	5	
Intersphincteric	0	0	0	0	1	1	0	4	2	0	0	0	8
Low transsphincteric	0	0	0	0	4	2	5	17	12	1	0	0	41
High transsphincteric	6	1	0	0	0	0	0	0	0	0	0	0	7
Suprasphincteric	2	0	0	0	0	0	0	0	0	0	0	0	2
Total	8	1	0	0	5	3	5	21	14	1	0	0	58

in Table 1a. Of the 446 patients who underwent definitive surgery for anal fistulas in the 6-year period between January 2010 and December 2015 at our hospital, 56 patients had anal fistulas with scrotal extension. All patients were male with a median age of 38 (range 13-80) years. Two patients had diabetes mellitus. The mean [± standard deviation (SD)] duration of anal fistulas was 54 ± 70 months. Eight patients (14.3%) had undergone previous definitive anal fistula surgery rather than simple drainage and were thus considered as having recurrent fistulas. There was a left-side predominance of scrotal involvement, with the side of the scrotum involved with the anal fistula as follows: right, 11 patients; left, 41 patients; midline, one patient; and bilateral, three patients. Twenty-one patients had multiple

anal fistulas. Preoperative MRI examinations were performed in 44 patients (78.6%; an example of MRI from one such patient is shown in Fig. 2).

The characteristics of fistulas with scrotal extension, including their Parks' classification and the location of the internal opening, are summarized in Table 1b. Two patients presented with multiple fistulas in which both fistulas extended independently and bilaterally. These cases were listed twice.

Forty-six (82.1%) of the 56 anal fistulas with scrotal extension had anterior internal openings (10 to 2 o'clock positions, (Table 1b, 2a), and all but one of the intersphincteric and low transsphincteric fistulas had anterior internal openings. In contrast, all high transsphincteric and suprasphinc-

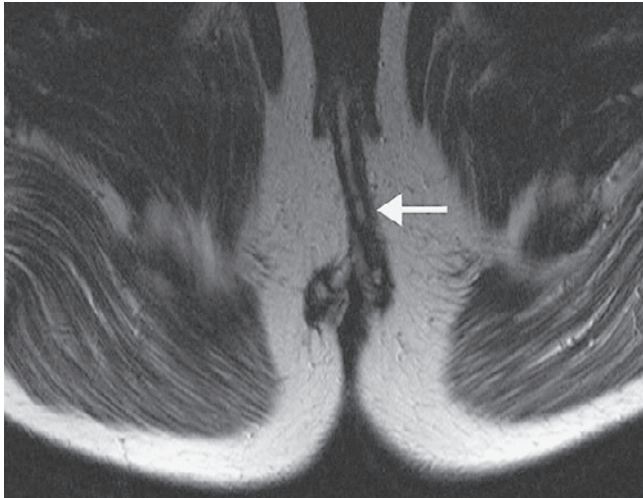


Fig. 2. Example of an axial T2-weighted magnetic resonance image of a low transsphincteric anal fistula extending into the scrotum. Two low transsphincteric anal fistulas with anterior internal openings at 10 and 2 o'clock positions are visible on this image. The anal fistula at 2 o'clock position extends into the left scrotum (arrow).

teric fistulas had posterior internal openings in the 6 to 7 o'clock positions. Four patients had recurrent fistulas classified as intersphincteric and low transsphincteric fistulas. Other four patients had recurrent fistulas classified as high transsphincteric and suprasphincteric fistulas. After excluding the eight patients with recurrent fistulas, 42 (87.5%) of the 48 anal fistulas with scrotal extension had anterior internal openings (Table 2b).

Considering the results in Table 1b, we divided all 446 patients who underwent definitive anal fistula surgery between January 2010 and December 2015 at our hospital according to whether they had anterior or posterior internal openings (109 and 337 patients, respectively). In the anterior group, 46 patients (42.2%) had anal fistulas with scrotal extension. In contrast, in the posterior group, only 10 patients (2.97%) had fistulas with scrotal extension. The RR of scrotal extension in the anterior group was 14.22 times higher than that in the posterior group (95% CI: 7.43-27.21). In the anterior group, the scrotal extension of anal fistulas was statistically significant ($p < 0.0001$; Table 2a). We also investigated the 374 patients who remained after excluding 72 patients with recurrent fistulas. In the anterior group, 42 patients (41.2%) had fistulas with scrotal extension. In contrast, in the posterior group, six patients (2.21%) had fistulas with scrotal extension. The RR of scrotal extension in the anterior group was 18.67 times higher than that in the posterior group (95% CI: 8.18-42.58). In the anterior group, the increased likelihood of scrotal extension of anal fistulas was statistically significant ($p < 0.0001$; Table 2b).

In all 446 patients, all high transsphincteric and suprasphincteric fistulas had posterior internal openings (data not shown). Therefore, we concluded that anal fistulas with scrotal extension must be mostly intersphincteric or low

Table 2.

a. Comparison of Two Groups in which All 446 Patients were Divided according to the Location of the Internal Opening.

We analyzed whether fistulas extended into the scrotum. In two patients with multiple fistulas, the fistulas extended bilaterally and independently. However, because multiple fistulas fell within the same Parks' classification (low transsphincteric) and internal opening category (anterior), they were listed only once.

Internal opening	Scrotal extension			RR	95% CI	p
	Yes	No	Total			
Anterior group	46	63	109	14.22	7.43-27.21	<0.0001
Posterior group	10	327	337			
Total	56	390	446			

b. Comparison of Two Groups in which 374 Patients, after Excluding 72 Patients with Recurrent Fistulas, were Divided according to the Location of the Internal Opening.

Internal opening	Scrotal extension			RR	95% CI	p
	Yes	No	Total			
Anterior group	42	60	102	18.67	8.18-42.58	<0.0001
Posterior group	6	266	272			
Total	48	326	374			

RR, relative risk; CI, confidence interval

transsphincteric, with anterior internal openings.

We further investigated the 46 patients of intersphincteric and low transsphincteric fistulas with anterior internal openings and scrotal extension (Table 3). Patients had a median age of 38 (range: 18-66) years and a mean disease duration of 57 ± 73 (mean \pm SD) months. Four patients (8.70%) had previously undergone definitive anal fistula surgery and were considered to have recurrent fistulas. The side of the scrotum involved with the anal fistula was as follows: right, eight patients; left, 34 patients; midline, one patient; and bilateral, three patients. As with all types of fistulas, intersphincteric and low transsphincteric fistulas predominantly involved the left side of the scrotum. Preoperative MRI examination was performed in 35 patients (76.1%; see Fig. 2 for an example). The number of patients within each subgroup according to Parks' classification were as follows: simple intersphincteric fistulas, six; intersphincteric fistulas with a high blind track, two; and low transsphincteric fistulas, 38. The locations of the internal openings are summarized in Table 1b. The median location of the anterior internal opening was the 1 o'clock position. Twenty-six patients had single fistulas, and 20 patients had multiple fistulas, the latter of which included two patients having double fistulas with independent scrotal extensions. Five patients underwent minimal seton surgery, and 41 patients underwent modified seton surgery with fistula division (Fig. 3). The median number of drainage seton bands used was two (range: 0-5), and the median number seton adjustments was three (range: 2-11). The median time at which the drainage seton bands were removed was the second seton adjustment (range: 1-5).

Table 3. Characteristics of Patients Having Intersphincteric and Low Transsphincteric Fistulas with Anterior Internal Openings and Scrotal Extension.

Two patients with multiple fistulas in whom fistulas extended bilaterally and independently were listed only once, except for the median location of the internal opening.

Characteristic	N=46
Sex	All male
Age (years), median (range)	38 (18-66)
Disease duration (months), mean ± SD	57 ± 73
Side of scrotum with fistula	
Right	8
Left	34
Midline	1
Bilateral	3
Parks' classification	
Simple intersphincteric	6
Intersphincteric with a high blind track	2
Low transsphincteric	38
Internal opening (o'clock), median (range)	1 (10-2)
Recurrent fistula	
Yes	4
No	42
MRI examination	
Yes	35
No	11
Multiple fistulas	
Yes	20
No	26
Surgery	
Minimal seton	5
Modified seton with fistula division	41
Median number of times of seton adjustment	3 (2-11)
Median number of drainage setons used	2 (0-5)
Median time of assessments at the time of drainage seton removal	2 (1-5)
Prognosis of anal fistulas	
Cured	46
Uncured	0
Continence	
Acceptable (0-10 in Wexner score)	46
Poor (11-20 in Wexner score)	0
Duration from operation to healing (days), mean ± SD	152 ± 79

Although a few patients experienced delayed wound healing and required insertion of additional drainage setons under local anesthesia, all fistulas were eventually cured. No patient experienced major postoperative incontinence. The mean time from surgery to confirmation of wound healing was 152 ± 79 (mean ± SD) days.

We examined surgical specimens from the dissected anal fistula of each of the two patients of the anterior group with scrotal extension. Histopathological analysis showed that the fistulous tract located between the external sphincter and scrotum ran in the Colles' fascia layer, but not in the subcutaneous fat (Fig. 4).

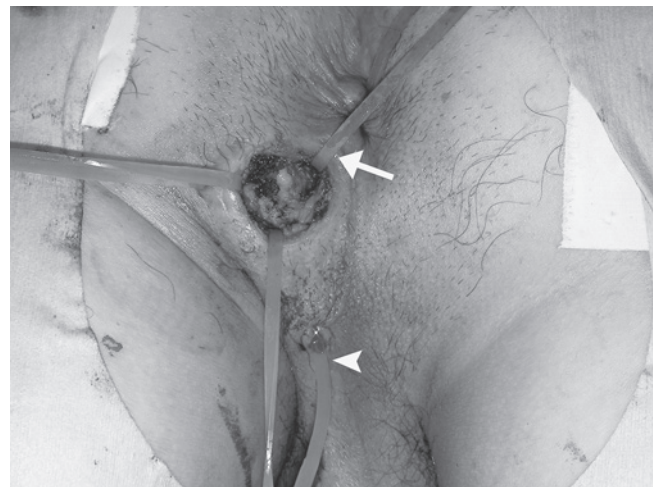


Fig. 3. Example of a modified seton surgery with fistula division. Low transsphincteric anal fistula with internal opening at 1 o'clock position extending into the left scrotum. A skin incision was made halfway along the fistulous tract, and the fistula was divided. A cutting seton (arrow) and a drainage seton (arrowhead) were inserted into the internal and external openings, respectively.

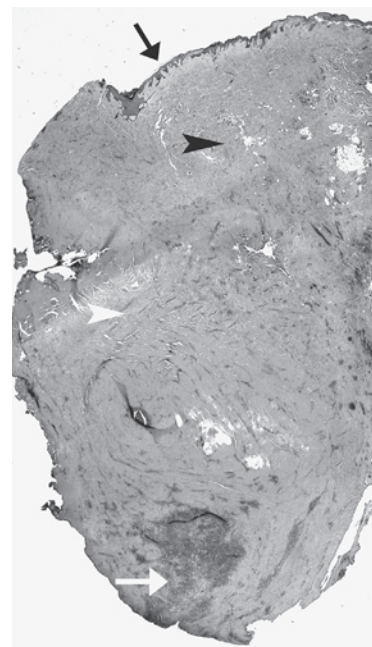


Fig. 4. Histopathology of a transversely dissected anal fistula located between the external sphincter and scrotum. Transverse section of an anal fistulous tract (white arrow) showing inflammatory cell infiltration in the Colles' fascia layer (white arrowhead), but not in the subcutaneous fat tissue (black arrowhead). The black arrow indicates the scrotal epidermis. Tissue is stained with 10× hematoxylin-eosin.

Discussion

The popular Goodsall's rule for predicting the trajectory of anal fistulas is widely applied; however, in clinical practice, some cases are incompatible with this rule^{1,2}. According to this rule, a transverse line is firstly drawn across the anus.

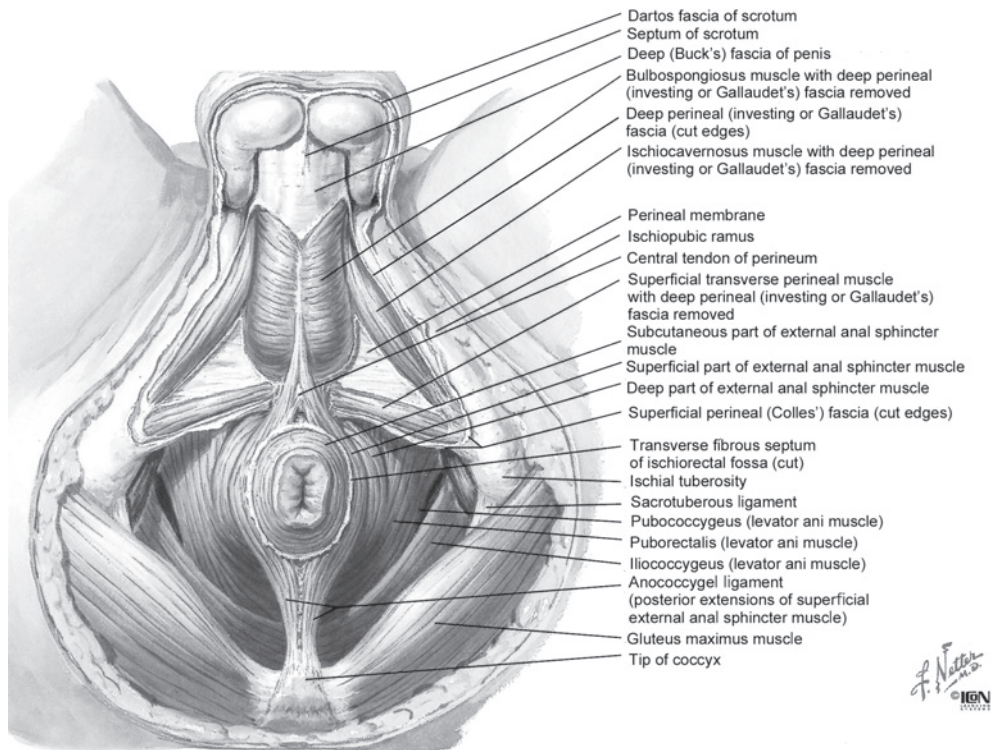


Fig. 5. Anatomy of the male perineum (reproduced with permission from Netter FH. Atlas of Human Anatomy. 6th ed.).

If the external opening of the fistula is located anterior to or on the transverse anal line, the internal opening will be on the same radial line. If the external opening exists posterior to the line, the internal opening will be on the posterior midline and the main fistulous tract will be curved to the external opening. However, long-tract anterior fistulas, and possibly fistulas with scrotal extension, are exceptions to this rule. Indeed, even if the external opening of a long anal fistula is located anterior to the transverse line, the fistulous tract may be curved to the internal opening in the posterior midline^{2,8)}. The objective of this study was to address whether anal fistulas with scrotal extension have a radial tract to the internal opening or a curved tract to the posterior midline.

Because Goodsall's rule is not compatible with all anal fistula cases, anal surgeons cannot entirely rely on this rule. Rather, this rule is considered as a guideline for diagnosing of the type of anal fistula. In general, a definitive diagnosis of the type of anal fistula is performed by palpation, MRI, or ultrasonography^{9,10)}. However, to our knowledge, there is no rule that guides the diagnosis of anal fistulas with scrotal extension. Therefore, we conducted this study to elucidate the characteristics of anal fistulas with scrotal extension.

We initially assumed that an increased proportion of high transsphincteric or suprasphincteric fistulas having posterior internal openings and primary abscesses would proceed into the scrotum. However, 46 (82.1%) of the 56 anal fistulas with scrotal extension were intersphincteric or low transsphincteric fistulas with an anterior internal opening. Only nine (16.1%) of the high transsphincteric or supras-

phincteric anal fistulas, which had an internal opening at the 6 to 7 o'clock positions, extended into the scrotum. After excluding recurrent fistulas, 42 (87.5%) of the 48 anal fistulas with scrotal extension had anterior internal openings. Therefore, Goodsall's rule, which states that anal fistulas with anteriorly located external openings have their internal openings in the same radial line, is applicable to anal fistulas with scrotal extension.

Based on the perineal anatomy (illustrated in Fig. 5), we can hypothesize why anal fistulas with scrotal extension are mostly low transsphincteric with anterior internal openings. The layers of the scrotum, from the surface to the testes, consist of the epidermis, dartos fascia, Colles' (superficial perineal) fascia, and external spermatic fascia. From our surgical and pathological findings, we confirmed that the path of the anal fistulous tract to the scrotum ran in the Colles' fascia layer, which is composed of soft connective tissue. In contrast, the dartos fascia is composed of hard connective tissue and smooth muscle. The Colles' fascia spreads over the anterior part of the superficial external sphincter muscle, the deep perineal (Gallaudet's) fascia, which encloses the superficial transverse perineal, bulbospongiosus and ischio-cavernosus muscles, and the external spermatic fascia. A low transsphincteric fistula with an anterior internal opening penetrates the superficial external sphincter and directly enters the Colles' fascia. The fistula proceeds through the Colles' fascia or through the potential space between the Colles' fascia and deep perineal fascia to the scrotum and finally opens at the scrotal epidermis¹¹⁾. Because the dartos fascia and scrotal skin are thick and hard, the fistula some-

times spreads along the Colles' fascia in the scrotum before opening externally. In contrast, high transsphincteric and suprasphincteric fistulas, which have their internal openings and primary abscesses located posteriorly, penetrate the external anal sphincter and then proceed anteriorly in the subcutaneous fat tissue of the ischioanal fossa but have difficulty in penetrating the Colles' fascia.

All fistulas with scrotal extension, including intersphincteric and low transsphincteric fistulas, predominantly extend to the left scrotum. Among intersphincteric and low transsphincteric fistulas, the median internal opening was located predominantly at the 1 o'clock position at the left side, even though the anatomy of the perineum is symmetrical. We surmise that the reason for this may be that the right hand is the dominant hand in most of the Japanese population¹²⁾, and thus, the left hip moves less than the right hip.

We performed modified seton surgery in which long intersphincteric and low transsphincteric fistulas with scrotal extensions were separated into two or more sections. The seton was adjusted every 2 weeks for a median of three times, and the drainage seton was completely removed at the second adjustment. All fistulas were eventually cured, and patients reported no major incontinence. The duration from surgery to the confirmation of healing was not excessively long and was tolerable for the patients. As anal fistulas and abscesses sometimes spread into the scrotum, careful exploration for such spreading and the insertion of additional drainage setons might be useful. A fistulotomy with the division of the external sphincter for such complicated transsphincteric fistulas can cause postoperative fecal incontinence^{13,14)} and necessitates a prolonged recovery period for adequate wound healing. Meanwhile, a simple seton surgery using one rubber band for long fistulas like these might take an excessively long period to transect the fistulous tract. We consider that the modified seton approach with fistula separation is an appropriate surgery for the treatment of anal fistulas with scrotal extension. However, a prospective randomized control trial using more patients and consistent postoperative assessment and follow-up is required to comprehensively assess the suitability of this approach.

Conclusion

Anal fistulas with scrotal extension were mostly low transsphincteric or intersphincteric anal fistulas with anterior internal openings. High transsphincteric or suprasphincteric fistulas, of which the internal opening was located posteriorly, rarely extended into the scrotum, except in cases of recurrent anal fistulas.

Acknowledgments: The authors wish to thank the staff of Rakuwakai Otowa Hospital.

Funding: The authors did not obtain any grants or funding for this study.

Conflicts of Interest

The authors declare that there are no conflict of interest.

References

1. Cirocco WC, Reilly JC. Challenging the predictive accuracy of Goodsall's rule for anal fistulas. *Dis Colon Rectum*. 1992 Jun;35(6):537-42.
2. Shinde PS. Management of rare, low anal anterior fistula exception to Goodsall's rule with Ksarasutra. *Anc Sci Life*. 2014 Jan-Mar;33(3):182-5.
3. Parks AG, Gordon PH, Hardcastle JD. A classification of fistula-in-ano. *Br J Surg*. 1976 Jan;63(1):1-12.
4. Kurihara H, Kanai T, Ishikawa T, et al. A new concept for the surgical anatomy of posterior deep complex fistulas: the posterior deep space and the septum of the ischioanal fossa. *Dis Colon Rectum*. 2006 Oct;49(10 suppl):s37-44.
5. Kagawa R, Nomura H, Takeda R, et al. [Anatomical course of deep anal fistulous tracts as analyzed by MRI]. *Nippon Daicho Komonbyo Gakkai Zasshi*. 2008 Apr;61(4):151-60. Japanese.
6. Tokunaga Y, Sasaki H, Saito T. Clinical role of a modified seton technique for the treatment of trans-sphincteric and supra-sphincteric anal fistulas. *Surg Today*. 2013 Mar;43(3):245-8.
7. Akagi K, Tsujinaka Y, Hamahata Y, et al. [Treatment for low intersphincteric anal fistula by seton method]. *Nippon Daicho Komonbyo Gakkai Zasshi*. 2010 Aug;63(8):488-93. Japanese.
8. Eisenhammer S. Long-tract anteroposterior intermuscular fistula. *Dis Colon Rectum*. 1964 Sep-Oct;7:438-40.
9. Barker PG, Lunniss PJ, Armstrong P, et al. Magnetic resonance imaging of fistula-in-ano: technique, interpretation and accuracy. *Clin Radiol*. 1994 Jan;49(1):7-13.
10. Buchanan GN, Halligan S, Bartram CI, et al. Clinical examination, endosonography, and MR imaging in preoperative assessment of fistula in ano: comparison with outcome-based reference standard. *Radiology*. 2004 Dec;233(3):674-81.
11. Netter FH. *Atlas of human anatomy*. 6th ed. Philadelphia, PA: Saunder/Elsevier; c2014. 329-97 p.
12. Tajika T, Kobayashi T, Yamamoto A, et al. Relationship between grip, pinch strengths and anthropometric variables, types of pitch throwing among Japanese high school baseball pitchers. *Asian J Sports Med*. 2015 Mar; 6(1): e25330.
13. Garcia-Aguilar J, Belmonte C, Wong WD, et al. Anal fistula surgery: factors associated with recurrence and incontinence. *Dis Colon Rectum*. 1996 Jul; 39(7): 723-9.
14. van Tets WF, Kuijpers HC. Continence disorders after anal fistulotomy. *Dis Colon Rectum*. 1994 Dec; 37(12): 1194-7.

Journal of the Anus, Rectum and Colon is an Open Access article distributed under the Creative Commons Attribution-NonCommercial-NoDerivatives 4.0 International License. To view the details of this license, please visit (<https://creativecommons.org/licenses/by-nc-nd/4.0/>).