

CASE REPORT

Endoanal Ultrasonography of Mucinous Adenocarcinoma Arising from Chronic Fistula-in-ano: Three Case Reports

Takayuki Toyonaga¹⁾, Ryuichi Mibu¹⁾, Hiromitsu Matsuda¹⁾, Yohei Tominaga¹⁾, Keiji Hirata¹⁾, Masafumi Takeyoshi²⁾, Masazumi Tsuneyoshi³⁾ and Makoto Matsushima⁴⁾

1) Department of Surgery, Fukuoka Sanno Hospital, Fukuoka, Japan

2) Department of Radiology, Fukuoka Sanno Hospital, Fukuoka, Japan

3) Department of Pathology, Fukuoka Sanno Hospital, Fukuoka, Japan

4) Department of Surgery, Matsushima Hospital Coloproctology Center, Yokohama, Japan

Abstract:

Mucinous adenocarcinoma arising in chronic fistula-in-ano is rare, and diagnosing it at an early stage is difficult. The role of endoanal ultrasonography in diagnosing the condition has not been discussed in the study. Herein, we report three cases of mucinous adenocarcinoma arising from anal fistulas in which endosonography played an important role in diagnosing malignant change. Three male patients with a 5- to 20-year history of anal fistula were referred to our hospital due to perianal induration, progressive anal pain, or mucopurulent secretion. In all three patients, endosonography revealed a multiloculated complex echoic mass with isoechoic solid components communicating with a trans-sphincteric fistula and sonography-guided biopsy under anesthesia revealed mucinous adenocarcinoma. All patients underwent abdominoperineal resection with lymph node dissection. One patient with a local recurrence died 3 years after surgery and two have remained disease-free for >6 years. These observations suggest that endosonography may be a reliable technique for the diagnosis of mucinous adenocarcinoma arising from chronic fistula-in-ano. Sonography-guided biopsy is useful for the definitive diagnosis of malignancy. Therefore, periodic endosonography assessment should be recommended for patients with persistent anal fistula, especially those with progressive clinical symptoms. Once malignancy is suspected, aggressive sonography-guided biopsy under anesthesia should be performed, which may enable an early diagnosis, curative treatment, and favorable long-term results.

Keywords:

anal fistula, mucinous adenocarcinoma, endosonography, sonography-guided biopsy

J Anus Rectum Colon 2017; 1(3): 100-105

Introduction

Mucinous adenocarcinoma associated with chronic fistula-in-ano is rare, and it is usually diagnosed at an advanced stage^{1,2)}. Mucinous tumors in the perianal region are usually not associated with anal bleeding or obstruction due to infrequent involvement of the rectal mucosa. Digital examination may reveal an area of induration on the side where the fistula is situated, but it cannot establish a conclusive diagnosis. Biopsy of the external opening of the fistulous tracts is not conclusive—and is quite often misleading—because

the tissue taken is quite superficial and only reveals an inflammatory reaction, especially when scarring and fibrosis are present³⁾. The main treatment is abdominoperineal resection and the prognosis depends on the stage of the tumor. In 80% of cases where the tumor is larger than 5 cm in diameter, the prognosis is poor⁴⁾. If the disease is localized, then wide excision of the tumor with abdominoperineal resection with or without adjuvant chemotherapy can provide favorable long-term results^{5,6)}. Thus, an early diagnosis is essential and treatment should be attempted without delay in an effort to achieve satisfactory results.

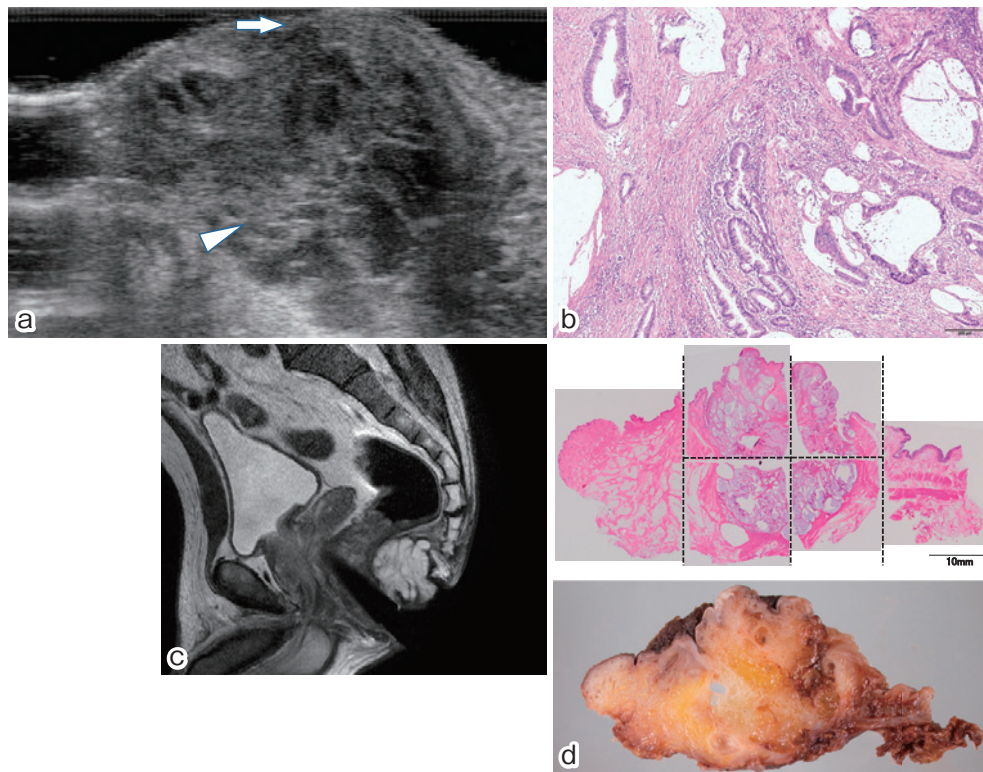


Figure 1. Mucinous adenocarcinoma arising from fistula-in-ano in a 54-year-old male (case 1). (a) EAUS showing irregular, multiloculated complex echoic mass located in the posterior ischiorectal fossa. The mass consists of multiple hypoechoic locules of various sizes, thin septations with a latticed appearance, and a variable amount of isoechoic solid components (arrowhead). The mass exhibits communication with a trans-sphincteric fistula with an internal opening at 6 o'clock (arrow). (b) Histological findings of endosonography-guided biopsy (hematoxylin-eosin stain, $\times 40$ magnification) showing mucinous adenocarcinoma. (c) T2-weighted MRI showing a markedly hyperintense heterogeneous mass located in the posterior ischiorectal fossa. (d) Macroscopic images of a surgical specimen depicting a multiseptated tumor with multiple mucous locules of various sizes.

Endoanal ultrasonography (EAUS) is considered to be a reliable technique for the assessment of fistula-in-ano and useful for distinguishing the condition from other inflammatory and tumorous conditions that affect the region around the anal canal⁷⁻¹². However, the role of EAUS in the diagnosis of mucinous adenocarcinoma arising from fistula-in-ano has not been reported.

In this case series, we demonstrate the characteristic EAUS findings in the three patients with mucinous adenocarcinoma arising from fistula-in-ano. We also describe the usefulness of sonography-guided biopsy under anesthesia for the definitive diagnosis of mucinous adenocarcinoma.

Three Case Reports

Case 1

A 54-year-old male with a 20-year history of anal fistula was referred to our hospital due to progressive anal pain and mucopurulent secretion. Two drainage operations had been

performed for perianal abscess in the past 20 years. Physical examination revealed an indurated lesion in the posterior perianal region, with an external opening at 6 o'clock and mucous discharge. EAUS was performed with SSD-Prosound 4000 (ALOKA, Tokyo, Japan) real-time system with a linear rectal probe with a 7.5-MHz transducer, and it revealed an irregular, multiloculated complex echoic mass with posterior enhancement and abrupt interface, 3.5×3.5 cm in size, located in the posterior ischiorectal fossa (Figure 1a). The mass consisted of multiple hypoechoic locules of various sizes, thin septations with a latticed appearance, and a variable amount of isoechoic solid components. The mass exhibited communication with a trans-sphincteric fistula with an internal opening at 6 o'clock. Sonography-guided biopsy from the multiloculated lesion taken under local anesthesia revealed mucinous adenocarcinoma (Figure 1b). Colonoscopy demonstrated no apparent lesions on the mucosal surface of the anal canal or rectum. Magnetic resonance imaging (MRI) revealed markedly hyperintense heterogeneous content with enhancing solid components, also suggesting

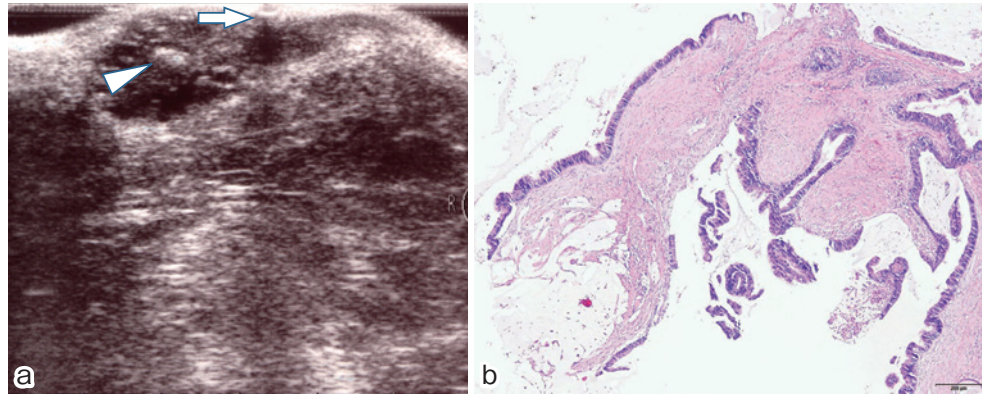


Figure 2. Mucinous adenocarcinoma arising from fistula-in-ano in a 48-year-old male (case 2).
 (a) EAUS showing trans-sphincteric fistula with an internal opening at 6 o'clock (arrow) and a multiloculated complex echoic mass with isoechoic solid components (arrowhead) located in the posterior ischioanal fossa.
 (b) Histological findings of endosonography-guided biopsy (hematoxylin-eosin stain, $\times 40$ magnification) showing mucinous adenocarcinoma.

mucinous adenocarcinoma, and showed no regional lymphadenopathy or distant metastases (Figure 1c). The patient then underwent abdominoperineal resection with lymph node dissection. Histological examination of the surgical specimen confirmed well-differentiated adenocarcinoma with mucin production (Figure 1d). The margins and the regional lymph nodes were free from malignant cells. The post-operative course was without complications, and the patient was doing well without any sign of recurrence 6 years after surgery.

Case 2

A 48-year-old male with a 10-year history of anal fistula was referred to our hospital due to progressive anal pain. Physical examination revealed an indurated lesion in the posterior perianal region, with two external openings, one at the 5 o'clock position and the other at the 7 o'clock position. EAUS revealed a trans-sphincteric fistula with an internal opening at 6 o'clock and a multiloculated complex echoic mass, 3×2 cm in size, with isoechoic solid components in the left posterior ischioanal fossa (Figure 2a). Sonography-guided biopsy from the multiloculated lesion taken under spinal anesthesia revealed mucinous adenocarcinoma (Figure 2b). The patient then underwent abdominoperineal resection with lymph node dissection. Histological examination of the surgical specimen confirmed well-differentiated adenocarcinoma with mucin production. The margins and the regional lymph nodes were free from malignant cells. The post-operative course was without complications, and the patient was doing well without any sign of recurrence 7 years after surgery.

Case 3

A 59-year-old male with a 5-year history of anal fistula was referred to our hospital due to progressive anal pain and swelling. One drainage operation had been performed for

perianal abscess 5 years prior. Physical examination revealed an indurated lesion with multiple external openings in the left posterior perianal region. EAUS revealed a trans-sphincteric fistula with an internal opening at 6 o'clock and a multiloculated complex echoic mass, 3×2 cm in size, with isoechoic solid components in the left posterior ischioanal fossa (Figure 3a). Sonography-guided biopsy from the multiloculated lesion taken under spinal anesthesia revealed mucinous adenocarcinoma (Figure 3b). The patient then underwent abdominoperineal resection. Histological examination of the surgical specimen confirmed well-differentiated to poorly differentiated adenocarcinoma with mucin production. The margins and the regional lymph nodes were free of malignant cells. The post-operative course was without complications, but the patient died due to peritoneal carcinomatosis 3 years after surgery.

Discussion

In the course of treating the three cases reported herein, we made two important clinical determinations: EAUS exhibits characteristic features in patients with mucinous adenocarcinoma arising from chronic fistula-in-ano, and sonography-guided biopsy under anesthesia is useful for the definitive diagnosis of malignancy. Each of these is discussed in sequence below.

In this study, we experienced three cases of mucinous adenocarcinoma associated with anal fistula in which EAUS characteristically depicts a multiloculated complex echoic mass communicating with a trans-sphincteric fistula. The characteristic imaging of the mass revealed multiple hypoechoic locules of various sizes, thin septations with a latticed appearance, and variable amounts of isoechoic solid components. It has been suggested that multiple hypoechoic locules reflect the mucin pool of mucinous adenocarcinoma. The most common differential diagnosis to perianal muci-

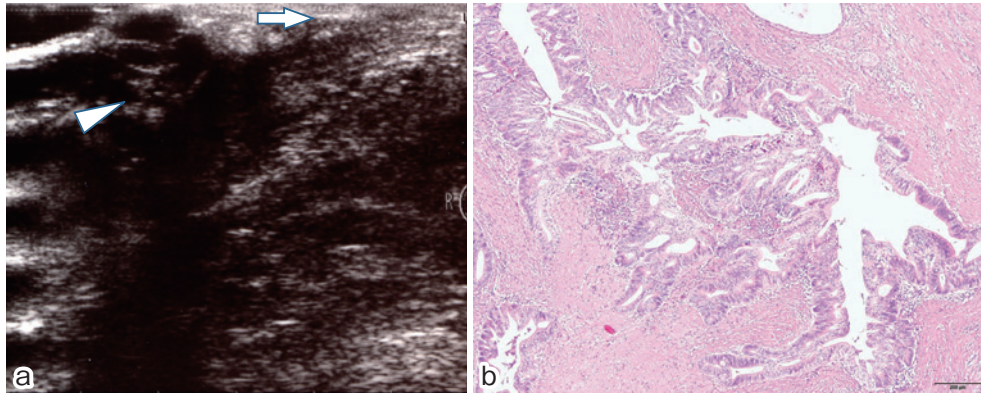


Figure 3. Mucinous adenocarcinoma arising from fistula-in-ano in a 59-year-old male (case 3).
 (a) EAUS showing a trans-sphincteric fistula with an internal opening at 6 o'clock (arrow) and a multiloculated complex echoic mass with isoechoic solid components (arrowhead) located in the left posterior ischioanal fossa.
 (b) Histological findings of endosonography-guided biopsy (hematoxylin-eosin stain, ×40 magnification) showing mucinous adenocarcinoma.

nous adenocarcinoma is perianal abscess associated with fistula-in-ano. Perianal abscess usually shows as a circumscribed, unilocular cystic mass (Figure 4a), and rarely presents a multilocular appearance (Figure 4b). The mass-like morphology of the solid tumor component in mucinous adenocarcinoma can be differentiated from the thin rim of the abscess wall. Chronic anal fistula shows as a hypoechoic tract that crossed the subepithelium, internal or external sphincters, and through the perianal space (Figure 4c). Other differential characteristics of perianal cystic masses include anorectal duplication, tailgut cyst, epidermoid cyst, dermoid cyst, lymphangioma, and cystic gastrointestinal stromal tumor (Figure 4d). Delineating the epicenter of the mass and its association with the bowel wall are helpful for narrowing down the differential diagnosis. Therefore, endosonographic assessment of fistula-in-ano is valuable not only for delineating the anatomy of the fistula tract and identifying areas of sepsis, but also for detecting associated tumors in extramural locations. To establish an early diagnosis and treatment of mucinous adenocarcinoma, periodic assessment with EAUS may be recommended for patients with long-standing fistula-in-ano, especially those with progressive anal pain, induration, or mucous discharge.

Sonography-guided biopsy under anesthesia is useful for the definitive diagnosis of malignancy. Mucinous adenocarcinoma in anal fistula is asymptomatic in its early stages and treatment requires abdominoperineal resection and colostomy, which severely compromises quality of life. Thus, the diagnosis should be careful and definitive as well as based on preoperative pathology findings where possible. Regrettably, the diagnosis of mucinous adenocarcinoma is often delayed due to failure to obtain a biopsy specimen^{1,3)}. Single biopsy analysis is associated with a high frequency of false negatives, and repeated biopsies are often required to make a definitive diagnosis. In this study, histological examinations of the multiloculated lesions using sonography-

guided biopsy proved malignancy in all three cases. As a result of their quick diagnoses, our patients underwent radical surgery during the localized stage resulting in negative surgical margins, no lymph node or distant metastases, and relatively favorable long-term outcomes. Therefore, to establish a definitive diagnosis of mucinous adenocarcinoma, sonography-guided biopsy under anesthesia may be recommended for patients with long-standing fistula-in-ano, when malignancy is suspected based on clinical manifestations, imaging findings, and mucin cytology.

Diagnostic implications of MRI for mucinous adenocarcinoma arising from fistula-in-ano have been described^{13,14)}, and characteristic MRI findings reportedly associated with the disease include markedly hyperintense fluid on T2-weighted images, enhancing solids components, and a fistula between the mass and the anus^{13,14)}. These imaging features were evident in one of the cases described herein. MRI is an accurate technique for the diagnosis of mucinous adenocarcinoma arising from fistula-in-ano and the evaluation of tumor invasion into the adjacent organs or a lymph node, or distant metastases. In clinical settings, however, EAUS has several advantages over MRI, such as lower costs associated with monitoring patients with long-standing fistula-in-ano, ease of use, applicability in either an outpatient setting or a surgical suite, and incorporation of image-guided biopsy of a suspicious specimen.

In conclusion, EAUS presents characteristic features in patients with mucinous adenocarcinoma arising from chronic fistula-in-ano, and sonography-guided biopsy under anesthesia is useful for the definitive diagnosis of malignancy. Therefore, periodic assessment with EAUS should be recommended for patients with long-standing fistula-in-ano, especially those with progressive clinical symptoms. Once malignancy is suspected, aggressive sonography-guided biopsy under anesthesia should be performed, which may enable an early diagnosis, curative treatment, and favorable long-term

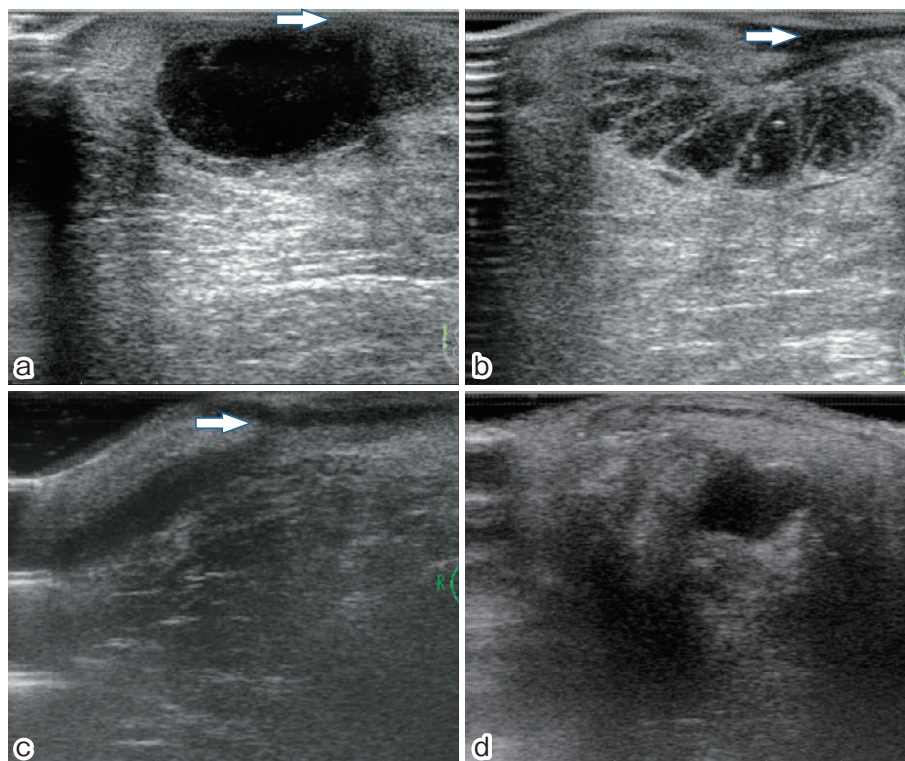


Figure 4. Differentials for a perianal cystic mass.

(a) Perianal abscess associated with anal fistula in a 60-year-old male.

EAUS showing a circumscribed, unilocular cystic mass located in the posterior ischioanal fossa with an internal opening at 6 o'clock (arrow).

(b) Perianal abscess associated with anal fistula in a 30-year-old male.

EAUS showing a circumscribed, multilocular cystic mass located in the posterior ischioanal fossa with an internal opening at 6 o'clock (arrow).

(c) Chronic trans-sphincteric fistula-in-ano in a 28-year-old male.

EAUS showing a hypoechoic tract in the left ischioanal fossa with an internal opening at 3 o'clock (arrow).

(d) Duplication cyst in a 67-year-old female.

EAUS showing a circumscribed, unilocular post-rectal cystic mass without communication to the bowel wall.

results.

Conflicts of Interest

There are no conflicts of interest.

Source of Funding

No funding was provided for this case series.

References

1. Getz SB, Jr., Ough YD, Patterson RB, et al. Mucinous adenocarcinoma developing in chronic anal fistula: report of two cases and review of the literature. *Dis Colon Rectum*. 1981 Oct;24(7):562-6.
2. Lee NK, Kim S, Kim HS, et al. Spectrum of mucin-producing neoplastic conditions of the abdomen and pelvis: cross-sectional imaging evaluation. *World J Gastroenterol*. 2011 Nov 21;17(43):4757-71.
3. Okada K, Shatari T, Sasaki T, et al. Is histopathological evidence really essential for making a surgical decision about mucinous carcinoma arising in a perianal fistula? Report of a case. *Surg Today*. 2008;38(6):555-8.
4. Marti L, Nussbaumer P, Breitbach T, et al. [Perianal mucinous adenocarcinoma. A further reason for histological study of anal fistula or anorectal abscess]. *Chirurg*. 2001 May;72(5):573-7.
5. Gaertner WB, Hagerman GF, Finne CO, et al. Fistula-associated anal adenocarcinoma: good results with aggressive therapy. *Dis Colon Rectum*. 2008 Jul;51(7):1061-7.
6. Ong J, Jit-Fong L, Ming-Hian K, et al. Perianal mucinous adenocarcinoma arising from chronic anorectal fistulae: a review from a single institution. *Tech Coloproctol*. 2007 Mar;11(1):34-8.
7. Buchanan GN, Halligan S, Bartram CI, et al. Clinical examination, endosonography, and MR imaging in preoperative assessment of fistula in ano: comparison with outcome-based reference standard. *Radiology*. 2004 Dec;233(3):674-81.
8. Gustafsson UM, Kahvecioglu B, Astrom G, et al. Endoanal ultrasound or magnetic resonance imaging for preoperative assessment of anal fistula: a comparative study. *Colorectal Dis*. 2001 May;3(3):189-97.
9. Law PJ, Talbot RW, Bartram CI, et al. Anal endosonography in the evaluation of perianal sepsis and fistula in ano. *Br J Surg*.

- 1989 Jul;76(7):752-5.
10. Toyonaga T, Tanaka Y, Song JF, et al. Comparison of accuracy of physical examination and endoanal ultrasonography for preoperative assessment in patients with acute and chronic anal fistula. *Tech Coloproctol*. 2008 Sep;12(3):217-23.
11. West RL, Zimmerman DD, Dwarkasing S, et al. Prospective comparison of hydrogen peroxide-enhanced three-dimensional endoanal ultrasonography and endoanal magnetic resonance imaging of perianal fistulas. *Dis Colon Rectum*. 2003 Oct;46(10):1407-15.
12. Engin G. Endosonographic imaging of anorectal diseases. *J Ultrasound Med*. 2006 Jan;25(1):57-73.
13. Hama Y, Makita K, Yamana T, et al. Mucinous adenocarcinoma arising from fistula in ano: MRI findings. *AJR Am J Roentgenol*. 2006 Aug;187(2):517-21.
14. Yamaguchi T, Kagawa R, Takahashi H, et al. Diagnostic implications of MR imaging for mucinous adenocarcinoma arising from fistula in ano. *Tech Coloproctol*. 2009 Sep;13(3):251-3.

Journal of the Anus, Rectum and Colon is an Open Access article distributed under the Creative Commons Attribution-NonCommercial-NoDerivatives 4.0 International License. To view the details of this license, please visit (<https://creativecommons.org/licenses/by-nc-nd/4.0/>).